Doppler US in Liver Transplantation: Evaluation for Donor

Ah Young Kim[1], M.D., Pyo Nyun Kim[2], M.D.,
[1]Department of Radiology, Seoul National University College of Medicine,

INTRODUCTION

Hepatic transplantations, either orthotopic or living-donor, are being performed with increasing frequency, leading to greater demand for accurate diagnostic information in preoperative and postoperative evaluation.

Doppler US is the primary screening imaging modality for preoperative evaluation of both donor and recipient. Especially, in living-related liver trans-plantations, vascular topographic evaluation of the donor is very important in determining the surgical plan and prognosis of the donor. In addition, Doppler US also plays a leading role in the postoperative evaluation of liver transplant patients because the clinical presentations of various post-transplantation complications are often nonspecific.

In this exhibit, we present the imaging role of Doppler US in the preoperative radiological assessment of recipient and donor, may it be cadaver or living-related, together with schematic drawing of surgical anatomy. And normal and abnormal postoperative Doppler US features including various postoperative vascular complications will be presented. Finally, the pitfalls of Doppler US evaluation and their clinical significance will be discussed.

GENERAL CONSIDERATION

INDICATIONS FOR LIVER TRANSPLANTATION

- Acute/chronic end-stage liver diseases
- Inborn errors of metabolism
- As an oncologic procedure

CONTRAINDICATIONS FOR LIVER TRANSPLANTATION

- Active alcohol or drug abuse
- Mesenteric venous thrombosis, complete
- Nonhepatic, non-neuroendocrine malignancies metastatic to liver
- Sepsis or Advanced systemic disease

** The presence of hepatocellular carcinoma is not a contraindication.*

SURGICAL ANATOMY

ORTHOTOPIC LIVER TRANSPLANTATION (OLTX)

- Cadaveric donor organ

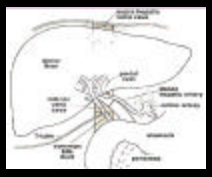

Fig 1. Basic vascular and biliary anastomoses. Suprahepatic vena cava, infrahepatic vena cava, portal vein, hepatic artery and biliary anastomosis.

Hepatic Artery of Donor

Hepatic Artery of Recipient

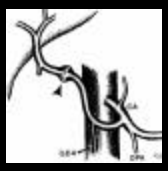

LIVING-RELATED LIVER TRANSPLANTATION (LRLT)

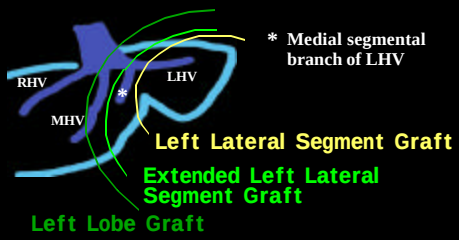

* Medial segmental branch of LHV

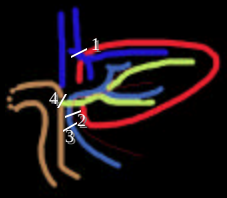

Fig 2. LRLT, Left lobe graft. Hepatic vein (1), hepatic artery (2), portal vein (3) anastomoses and hepaticojejunostomy of biliary tree (4).

Living-related liver transplantation with Left lateral segment graft ~ left lobe graft is commonly used in pediatric recipient for liver transplantation. Decision of extent and design of segmental resection of the liver depends on volume of required liver and vascular anatomy, particularly venous anatomy.

- Other LRLT Methods
  - Right Lobe Graft
  - Extended Left Lobe Graft
  - Extended Right Lobe Graft

PREOPERATIVE DOPPLER US

The main objectives of preoperative radiologic evaluation include (1) assessment of vessel patency for surgical planning, (2) identification of cirrhosis and sequella of portal hypertension and (3) search for intra- and extrahepatic malignancy.

FOR RECIPIENT

- To assess the patency of PV, HV and IVC
- To assess vascular anatomy of HA
- To detect malignancy
- Evaluate hepatofugal flow, other changes of portal hypertension, varices, intractable ascites

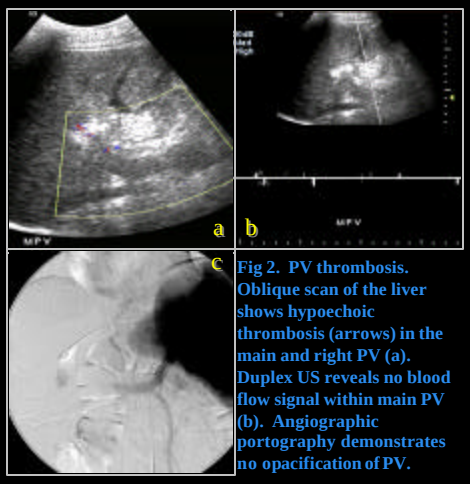

Fig 2. PV thrombosis. Oblique scan of the liver shows hypoechoic thrombosis (arrows) in the main and right PV (a). Duplex US reveals no blood flow signal within main PV (b). Angiographic portography demonstrates no opacification of PV.

FOR DONOR

- OLTX
  - Liver disease like fatty liver
  - Vascular patency and anomaly
- LRLT
  - Vascular topographic evaluation

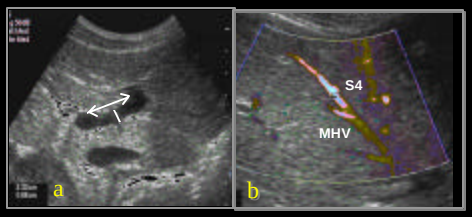

Fig 3. Vascular topographic evaluation for LRLT, left lobe. The length (↕) and diameter (|) of left PV are measured (a). The number and course of segmental HV draining of S4 as well as anomalous HV is carefully evaluated to decide operative planning (b).

Imaging Roles in Pre- & Postoperative and Recipient

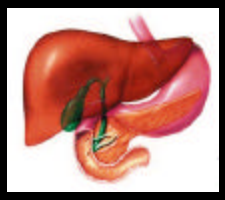

Hyun Kwon Ha[2], M.D., Moon-Gyu Lee[2], M.D.
[2]Department of Diagnostic Radiology, University of Ulsan, Asan Medical Center

DOPPLER US : NORMAL FINDINGS

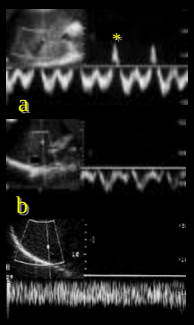

Fig 4. Various HV Doppler spectrum. Classic triphasic waveform of a normal patient includes a transient phase of reversed flow away from the IVC during right heart contraction (*) (a) can be changed. Loss of reversed flow (b) or monophasic flow (c) can be seen due to respiratory phase, intraperitoneal pressure, or severity of liver cirrhosis.

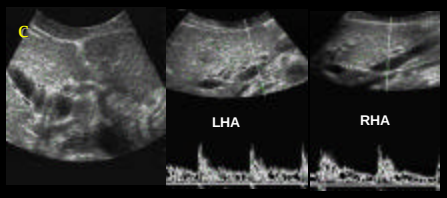

Fig 5. Assessment of HA. The detection of anomalous vascular origin or stenosis at celiac axis is very important in deciding operative plan.

POSTOPERATIVE DOPPLER US

US is the primary screening technique for detection of vascular complications of hepatic transplantation. Angiography is used to confirm the US findings or when the US study is suboptimal.

HEPATIC ARTERY THROMBOSIS

- Most common, most serious complication
- 4-12% in adults, 42% in pediatrics
- US findings: biloma, infarctions, abscess
- Doppler US: accuracy 92%

  Absent arterial flow at the porta hepatis with a tardus parvus waveform for the intrahepatic arterial (IHA) flow.

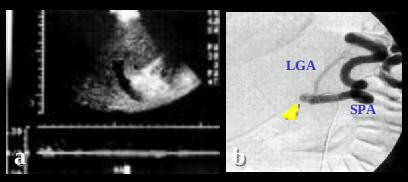

Fig 6. Hepatic arterial thrombosis. Doppler US shows no flow signal along hepatic artery, particularly at porta hepatis (a). Celiac arteriography demonstrates complete occlusion (⇗) at common hepatic arterial level (b). This patient underwent re-surgery for vascular graft.

HEPATIC ARTERY STENOSIS

- 11%, anastomotic site
- Doppler US:

  Focal accelerated velocity (> 2-3 m/sec) with associated turbulence at or distal to stenosis

  Tardus parvus pattern of IHA

  ⟶ RI < 0.5, SAT > 0.08

  systolic acceleration time

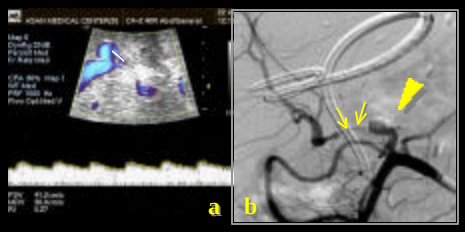

Fig 7. Stenosis of right hepatic artery (RHA) in LRLT, right lobe. Doppler US shows characteristic tardus parvus waveform of RHA, just above anastomotic site (low RI, prolonged SAT) (a). Angiogram demonstrates severe stenosis of RHA (arrows) at anastomotic site as well as pseudoaneurysm (arrowhead) (b).

PORTAL VEIN THROMBOSIS/STENOSIS

- 1-13%, anastomotic site
- Doppler US :

  PV thrombosis ⟶ Echogenic thrombus

  PV stenosis ⟶ PV diameter < 2.5 mm

  acceleration of PV flow at stenosis

  or post-stenotic jet of PV flow

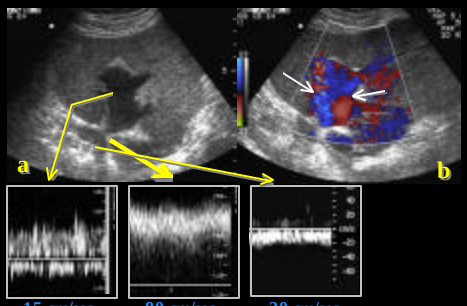

Fig 8. PV Stenosis in LRLT, left lobe. Poststenotic ballooning of left PV shows high flow velocity at stenotic portion (a) and turbulent color flow (arrows) (b). Angiogram reveals focal stenosis (arrow) of PV at anastomotic site with pressure gradient of 7 mm Hg.

IVC OR HEPATIC VEIN STENOSIS

- Doppler US :

  Acceleration of pre-stenotic flow (x 3~4)

  Loss of normal phasicity of post-stenotic flow

  Flow reversal of HV flow, loss of phasicity of HV ⟶ suprahepatic caval stenosis

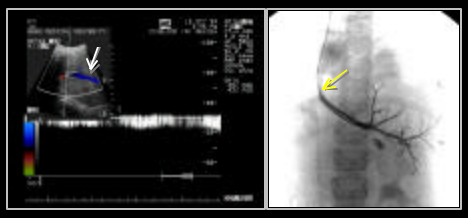

Fig 9. HV Stenosis in LRLT, left lobe. Loss of normal triphasic waveform of HV is seen with reversed color flow (arrow) (a). Hepatic venography shows focal stenosis at anastomotic site (arrow) between HV and IVC with pressure gradient of 7 mm Hg (b).

PITFALLS

- Severe hepatic edema, systemic hypotension, high-grade HA stenosis and technical imitation mimic HA thrombosis.
- Low RI and prolonged SAT is normally appeared during or within 48 hrs after op.
- Increased flow velocity of HA mimicking HA stenosis is normally seen due to size discrepancy between donor and recipient vessels

CONCLUSION

Doppler US, the primary imaging modality, plays the leading role in the preoperative and postoperative evaluation of liver transplant patients as well as donors. Exact knowledge and early recognition of various complications help the next logical imaging test to confirm or help choose the most appropriate intervention to preserve normal graft function.